

Main Article

Dr B Karabulut takes responsibility for the integrity of the content of the paper

Cite this article: Karabulut B, Deveci İ, Sürmeli M, Şahin-Yilmaz A, Oysu Ç. Comparison of functional and oncological treatment outcomes after transoral robotic surgery and open surgery for supraglottic laryngeal cancer. *J Laryngol Otol* 2018;**132**:832–836. <https://doi.org/10.1017/S0022215118001305>

Accepted: 26 March 2018
First published online: 8 August 2018

Key words:

Laryngectomy; Robotic Surgical Procedures; Treatment Outcome

Author for correspondence:

Dr Burak Karabulut,
Ümraniye Eğitim ve Araştırma Hastanesi, KBB Hastalıkları Kliniği, Adem Yavuz Cad. No: 1,
Ümraniye, İstanbul, Türkiye
E-mail: kbbturk@yahoo.com

Comparison of functional and oncological treatment outcomes after transoral robotic surgery and open surgery for supraglottic laryngeal cancer

B Karabulut, İ Deveci, M Sürmeli, A Şahin-Yilmaz and Ç Oysu

Otolaryngology Department, University of Health Sciences, Ümraniye Education and Research Hospital, İstanbul, Turkey

Abstract

Objective. To compare functional and oncological treatment outcomes among patients with supraglottic laryngeal cancers who underwent transoral robotic supraglottic laryngectomy and open supraglottic laryngectomy.

Methods. A retrospective chart review was conducted of 17 patients treated by transoral robotic supraglottic laryngectomy and 20 patients treated by open supraglottic laryngectomy.

Results. No tracheostomy or prolonged intubation was needed in the transoral robotic surgery group. Furthermore, that group had a shorter oral feeding time, hospitalisation and recovery period. There was no difference between groups in terms of complications. There were no differences in overall survival time and disease-specific survival time between groups.

Conclusion. Transoral robotic supraglottic laryngectomy for supraglottic laryngeal cancer is an oncologically safe and functional procedure with better results when compared to conventional open surgery.

Introduction

Treatment modalities for supraglottic squamous cell carcinoma include open supraglottic laryngectomy, transoral laser surgery, transoral robotic surgery and primary chemoradiotherapy.¹

Radiotherapy (RT) and chemoradiotherapy have increasingly been used to treat laryngopharyngeal cancers located in the supraglottic region in the last few decades; however, these treatment modalities have several negative effects. Even long after treatment cessation, the persistence of severe mucositis, pain and dysphagia may be debilitating.^{2,3} The absence of pathological verification of nodal status in the neck may result in overtreatment with full curative radiation to both sides of the neck, in light of the significant possibility of regional metastasis. If radiation is used early as a primary treatment for resectable tumours, RT will not be an option when second tumours arise, which occurs in a significant portion of these patients.

Transoral laser surgery for supraglottic laryngeal tumours has been described by Weinstein and colleagues.⁴ Despite its advantages, transoral laser surgery has some limitations, such as piecemeal resection of the tumour, manipulation of tissue only by one hand, the risk of disorientation of an unexperienced surgeon during surgery, and limited linear resection ability associated with the use of a microscope and laser light.

In addition to laser surgery, transoral robotic surgery has also been investigated for the treatment of supraglottic laryngeal carcinoma. Feasibility of the surgery has been verified, and early oncological and functional outcomes are encouraging.^{4–7} Advantages of transoral robotic surgery include: high-quality three-dimensional imagination, wide exposure, en bloc resection of even big tumours, tremor filtration and free movement of angulated robotic arms.

The current study aimed to compare the functional and oncological outcomes of transoral robotic supraglottic laryngectomy and open supraglottic laryngectomy in patients with supraglottic carcinoma.

Materials and methods

Study design

A retrospective chart review was conducted of all patients with supraglottic carcinoma treated at our institute. All patients were discussed at the Tumor Board of the University of Health Sciences Head and Neck Cancer Center to work out a multidisciplinary treatment plan.

Surgical treatment was recommended to patients, having taken into account the following factors: patients' preference, morbidity related to chemoradiotherapy, general

performance and so on. All transoral robotic supraglottic laryngectomies were performed by one head and neck surgeon (CO). Open supraglottic laryngectomies were performed by two head and neck surgeons (BK and İD). Informed patients' overall preferences, patients' insurance status (robotic surgery is not covered by the national social insurance system) and access to the robotic surgery system (which is not available for all operation days) were considered when making decisions regarding the surgical method.

Patient population

The charts of patients with supraglottic carcinoma operated on between May 2010 and June 2014 were reviewed. During this period, 17 patients underwent transoral robotic supraglottic laryngectomy and 20 patients underwent open supraglottic laryngectomy.

Inclusion and exclusion criteria

All patients who underwent transoral robotic supraglottic laryngectomy or open supraglottic laryngectomy with curative intent for supraglottic squamous cell carcinoma were included in the study. There were no exclusion criteria.

Transoral robotic surgery

In the robotic surgery group, the da Vinci Robotic System (Intuitive Surgical, Sunnyvale, California, USA) was set as reported by Park *et al.*⁸ Transoral robotic supraglottic laryngectomy was performed as previously described.^{4,5}

Transnasal intubation was preferred to keep the intubation tube away from the surgical area. A transoral Feyh-Kastanbauer retractor (Gyrus ACMI, Southborough, Massachusetts, USA) was used for wide exposure. A 30-degree, up-facing, binocular robotic camera, Maryland dissector and monopolar cautery spatula arm were used.

The first incisions were made superior to the ventral base of the epiglottis in a horizontal direction. The incision was continued through the pre-epiglottic space, up to hyoid bone and along the aryepiglottic folds. Dissection was continued inferiorly to the petiole of the epiglottis. Contralateral incisions were made above the glottis, into the ventricle and around the lesion. The specimen was resected and removed from the surgical field. The Maryland dissector and monopolar cautery spatula arm were used for all transoral robotic supraglottic laryngectomies.

Negative intra-operative margins were confirmed by histopathological analysis in all patients.

Open surgery

Open supraglottic laryngectomy was performed as reported by Alonso.⁹ The procedure involved resection of supraglottic laryngeal tissues, including the false vocal folds, epiglottis and aryepiglottic folds, with the upper one-third of thyroid cartilage, by a transcervical approach. After resection, the remaining laryngeal tissues were approximated to the tongue base with sutures passing beyond the hyoid bone.

Neck treatment

Bilateral neck dissections were performed on all patients in light of the occult metastatic nature of the disease. The open

supraglottic laryngectomy group underwent the neck dissections concurrently, but the transoral robotic supraglottic laryngectomy group underwent the neck dissections two to three weeks after the operation.

Post-operative adjuvant therapy

Indications for adjuvant RT, with or without chemotherapy, were based on histopathological evaluation of paraffin-embedded sections. It was recommended for patients with any of the following conditions: stage III or IV disease, extracapsular nodal spread, multiple lymph node involvement, or peri-neural or lymphovascular invasion.

Statistical methods

Age, sex, primary tumour subsite, tracheostomy requirement, decannulation time, oral feeding time, hospitalisation duration, additional therapies, follow-up period, early and late complications, and survival rates were recorded for both groups.

The Kolmogorov–Smirnov test was used to determine whether data were normally distributed. The Mann–Whitney U test was used to compare the continuous variables between the two groups. A *p*-value of less than 0.05 was considered statistically significant. Statistical analyses were performed using the SPSS software package (version 19.0; SPSS, Chicago, Illinois, USA).

Results

Patients' characteristics

Patients' clinical characteristics are shown in Table 1. The mean age of patients was 62.2 years (range, 53–86 years) for the transoral robotic supraglottic laryngectomy group and 57.5 years (range, 39–78 years) for the open supraglottic laryngectomy group. The transoral robotic surgery and open surgery groups consisted of 2 (11 per cent) and 2 (10 per cent) females, respectively. The groups were similar in terms of age and gender distribution (*p* = 0.08 and *p* = 0.86 respectively).

In the transoral robotic surgery group, the primary tumour involved: the epiglottis (*n* = 9, 52 per cent), the epiglottis and aryepiglottic fold (*n* = 4, 25 per cent), the epiglottis and false vocal fold (*n* = 2, 11 per cent), and the tongue base and vallecula (*n* = 2, 11 per cent). In the open surgery group, it involved: the epiglottis (*n* = 6, 30 per cent), the epiglottis and aryepiglottic fold (*n* = 5, 25 per cent), the epiglottis and false vocal fold (*n* = 5, 25 per cent), and the vallecula and tongue base (*n* = 4, 20 per cent).

All patients underwent selective neck dissection, including levels II, III and IV, or modified radical neck dissections, bilaterally.

Tumours were staged according to the guidelines of the American Joint Committee on Cancer. In the transoral robotic supraglottic laryngectomy group, five patients were tumour stage T₁, four were T₂ and eight were T₃. In the open supraglottic laryngectomy group, 4 patients were T₁, 6 were T₂ and 10 were T₃. Regarding tumour–node–metastasis (TNM) stage, in the transoral robotic surgery group one patient was stage I, three were stage II, nine were stage III, three were stage IVa and one was stage IVb. In the open surgery group, 2 patients were stage I, 3 were stage II, 11 were stage III, 3

Table 1. Clinical and pathological data for robotic and open surgery groups

Characteristics	Transoral robotic supraglottic laryngectomy*	Open supraglottic laryngectomy†	<i>p</i>
Sex			0.86
– Male	15	18	
– Female	2	2	
Mean age (years)	62.2	57.5	0.08
Primary subsite			0.14
– Epiglottis	9	6	
– Aryepiglottic fold	4	5	
– False vocal fold	2	5	
– Tongue base	2	4	
Tumour (T) stage‡			0.69
– T ₁	5	4	
– T ₂	4	6	
– T ₃	8	10	
TNM stage			0.78
– I	1	2	
– II	3	3	
– III	9	11	
– IVa	3	3	
– IVb	1	1	

Data represent numbers of patients, except where indicated otherwise. **n* = 17; †*n* = 20.

‡Pathologically confirmed. TNM = tumour–node–metastasis

were stage IVa and 1 was stage IVb. There was no significant difference in tumour stage or tumour involvement subsites between groups ($p = 0.78$ and $p = 0.14$ respectively, Table 1).

Thirteen patients in the transoral robotic surgery group and 15 patients in the open surgery group received adjuvant RT, with or without chemotherapy. This was because one or more of the following conditions were present: stage III or IV disease, multiple lymph node involvement, and/or extracapsular spread.

Tumours were successfully removed in all patients. Multiple frozen biopsy specimens were studied. Negative margins were achieved intra-operatively in all patients.

Functional outcomes

We did not perform tracheostomy in the transoral robotic supraglottic laryngectomy group. However, one patient in this group required tracheostomy six months after the surgery because of bilateral vocal fold paralysis induced by RT. Patients in the open supraglottic laryngectomy group routinely had intra-operative tracheostomy. Mean decannulation time for the open surgery group was 34.7 days (range, 12–75 days).

Mean removal of the feeding tube occurred at 7 days (range, 0–12 days) in the transoral robotic supraglottic laryngectomy group and at 12.2 days (range, 7–53 days) in the open supraglottic laryngectomy group. There was a significant difference in oral feeding duration between groups ($p < 0.01$; Figure 1).

Mean hospitalisation duration was 8.8 days (range, 0–14 days) and 14.7 days (range, 7–35 days) for the transoral robotic supraglottic laryngectomy group and the open supraglottic

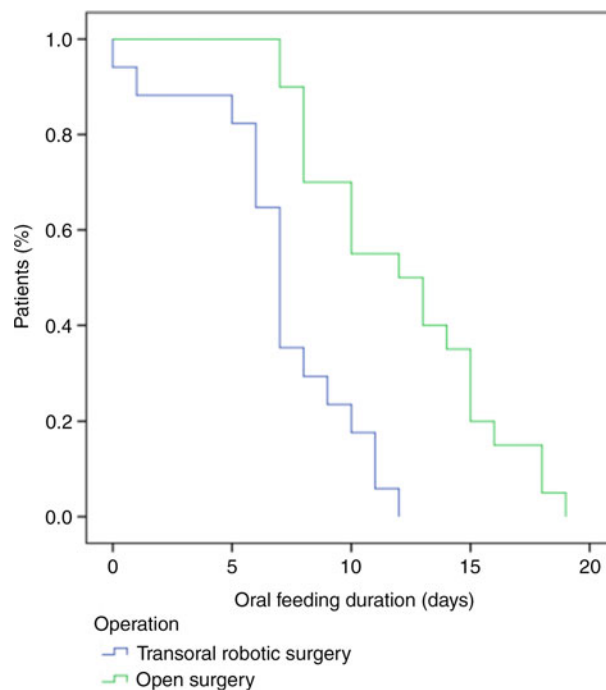


Fig. 1. Comparison of oral feeding duration for the transoral robotic supraglottic laryngectomy group and the open supraglottic laryngectomy group revealed a significant difference between the groups ($p < 0.01$).

laryngectomy group, respectively; this difference was statistically significant ($p = 0.001$).

Treatment outcomes and overall survival

Mean follow-up duration was 25.8 months (range, 0–84 months) for the transoral robotic supraglottic laryngectomy group and 41 months (range, 21–82 months) for the open supraglottic laryngectomy group. One patient in the transoral robotic surgery group died on post-operative day 2 because of acute renal insufficiency. One patient from each group died following regional recurrence in the neck. Pathological assessment showed N₃ neck involvement in both of these patients. All other patients were alive and disease-free when these data were collected.

The overall survival rate was 88 per cent for the transoral robotic supraglottic laryngectomy group and 95 per cent for the open supraglottic laryngectomy group. The disease-specific survival rate was 94 per cent for the robotic surgery group and 95 per cent for the open surgery group. There was no difference between groups in terms of overall survival and disease-specific survival rates ($p = 0.22$ and $p = 0.49$, respectively; Figures 2 and 3).

There were no peri-operative complications in either group. No conversion from robotic surgery to an open approach was required in any patient. Two patients from the open surgery group and one patient from the robotic surgery group had pneumonia. One patient in the transoral robotic supraglottic laryngectomy group had vocal fold paralysis due to RT at six months post-operatively.

Discussion

Organ preservation, in addition to curing the cancer, is one of the main considerations in the treatment of supraglottic laryngeal carcinoma. Modern surgical treatments include transoral

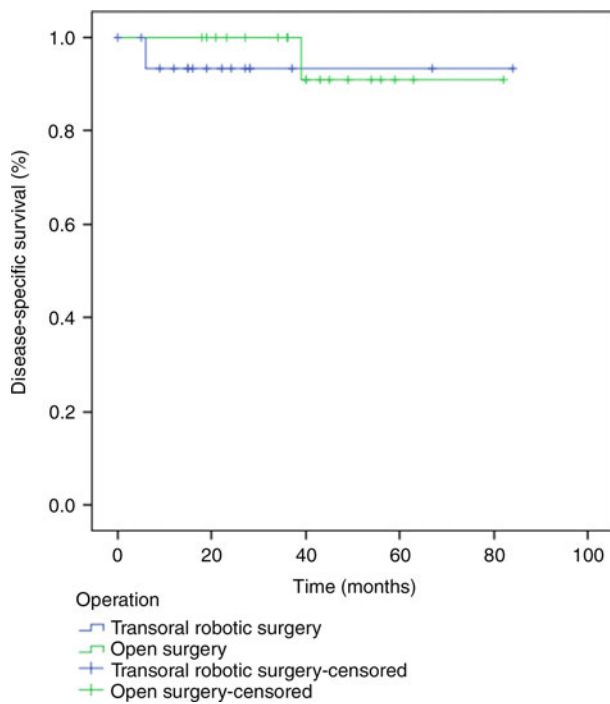


Fig. 2. Disease-specific survival for the transoral robotic supraglottic laryngectomy group and the open supraglottic laryngectomy group, analysed using the Kaplan-Meier method and compared using the log rank test ($p = 0.49$).

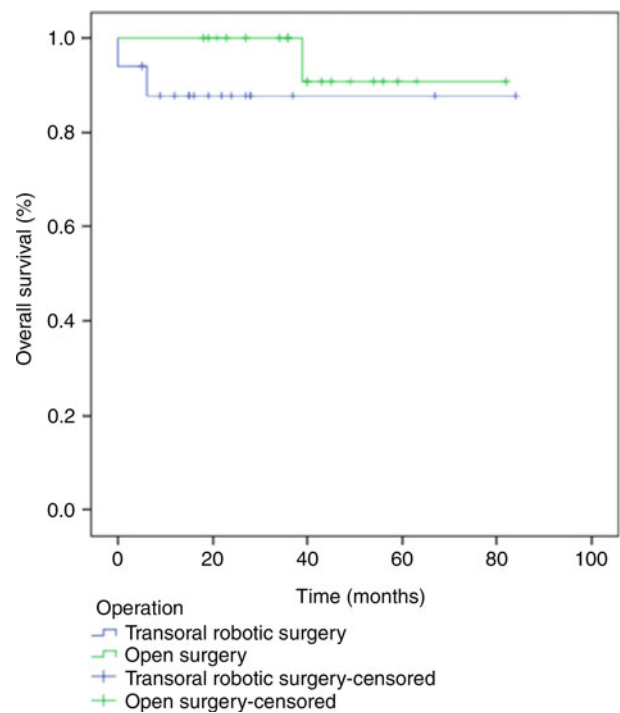


Fig. 3. Overall survival for the transoral robotic supraglottic laryngectomy group and the open supraglottic laryngectomy group, analysed using the Kaplan-Meier method and compared using the log rank test ($p = 0.22$).

laser surgery, transoral robotic supraglottic laryngectomy and conventional open supraglottic laryngectomy. The outcome of these surgical modalities should be comparable to results obtained with total laryngectomy. In addition, respiration, phonation and swallowing function should be retained in order to improve the patients' quality of life.

- Transoral robotic supraglottic laryngectomy provides a shorter recovery time for supraglottic laryngeal cancer patients than conventional surgery
- The main limitation of the procedure is inadequate exposure
- Robotic surgery for T₄ supraglottic cancer has been described in the literature
- However, we maintain robotic supraglottic laryngectomy is more appropriate for tumours without extralaryngeal involvement

Traditionally, open surgery was the only surgical option for supraglottic laryngeal cancers. Open supraglottic laryngectomy is a well-defined surgery, and is still an option in some circumstances. However, the introduction of transoral surgical procedures for supraglottic lesions has shifted the surgical approach.

Transoral robotic supraglottic laryngectomy was introduced for supraglottic laryngeal cancer over a decade ago. It was originally described by Weinstein *et al.* for the treatment of T₁, T₂ and selected T₃ tumours of the supraglottic larynx.⁴

In our patient series, a temporary peri-operative tracheostomy was not needed in patients who underwent transoral robotic surgery. In contrast, the average decannulation time for open supraglottic laryngectomy was 34.7 days. Park *et al.* performed temporary tracheostomy on all patients who underwent transoral robotic supraglottic laryngectomy, with tube removal occurring at an average of 9 days post-operatively.¹⁰ Decannulation times were shorter in the transoral robotic

surgery group than in open conventional surgery group.¹⁰ Some authors have preferred long intubation times after surgery, with an average extubation time of 24–48 hours instead of tracheostomy for transoral robotic supraglottic laryngectomy.^{11,12} A recent multicentre study of transoral robotic supraglottic laryngectomy reported that 24 per cent of the patients had temporary tracheostomy for an average of 8 days.¹³ However, the indications for tracheostomy were not clear in that study. This may be because of the nature of multicentre data collection and surgeon preference. Although we did not perform any peri-operative tracheostomies in the robotic surgery group, we believe that decisions about performing it should be made according to the patient.

Our mean follow-up period was 25.8 months for the transoral robotic supraglottic laryngectomy group and 41 months for the open supraglottic laryngectomy group. One patient in the robotic surgery group died at day 2 post-operatively because of acute renal insufficiency. There was one death in each group as a result of neck recurrence of N₃ neck disease. There was no difference between the groups in overall survival or disease-specific survival rates.

Park *et al.* reported a mean follow-up period of 27.3 months for transoral robotic supraglottic laryngectomy patients; in addition, they did not find any significant difference in overall survival or disease-free survival rates between transoral robotic surgery and open surgery groups.¹⁰ The largest case series of patients who underwent transoral robotic supraglottic laryngectomy was reported by a French research group, but their mean follow-up period was short (14 months) and they did not report any survival rates, possibly because of the relatively short follow-up periods.¹³ Based on these findings, and the lack of any difference in survival rates between the transoral robotic surgery group and the open surgery group in our study, we suggest that transoral robotic supraglottic laryngectomy provides acceptable oncological results in comparison with open supraglottic laryngectomy.

Nasogastric tube dependence is one of the factors determining hospitalisation duration. In our study, nasogastric tube dependence was significantly shorter in the robotic surgery group because of the faster recovery of swallowing ability. Our patients in the transoral robotic surgery group were able to tolerate oral feeding at an average of 7 days (range, 0–12 days). None of our patients required gastrostomy. The aforementioned French research group reported that 24 per cent of patients who underwent transoral robotic supraglottic laryngectomy were able to start an oral diet within 24 hours of surgery, without a feeding tube requirement.¹³ The remaining patients had a nasogastric tube, with a median use of 8 days, and 9.5 per cent had definitive percutaneous endoscopic gastrostomy feeding.¹³ Park *et al.* also reported shorter swallowing recovery times for the transoral robotic supraglottic laryngectomy group than the open supraglottic laryngectomy group.¹⁰ Kayhan *et al.* were able to start oral feeding at a mean of 10.8 days in 13 patients who underwent transoral robotic supraglottic laryngectomy.¹² Ozer *et al.* reported that they were able to start oral feeding in all patients ($n = 13$) at post-operative day 1; however, two of the patients did not tolerate oral feeding and one of them needed temporary gastrostomy tube placement.⁶ We were not able to start an oral diet as soon as stated in these reports. Although the results of robotic surgery are better than those of open surgery, the robotic surgery patients still required intense swallowing therapy after the surgery.

One of the most precise reports regarding swallowing in transoral robotic supraglottic laryngectomy patients came from Mendelsohn *et al.*¹⁴ They reported that patients required 2–29 days (median, 4.5 days) for safe swallowing of solids, and 2–45 days (median, 5.5 days) for safe swallowing of thin liquids. They also concluded that gender, tumour (T) stage, simultaneous neck dissection and vocal fold hypomobility affect post-operative swallowing rehabilitation in transoral robotic surgery patients.¹⁴

Length of hospitalisation has a considerable financial burden on the national healthcare system. The average hospital stay for the transoral robotic surgery group was shorter than in the open surgery group. However, this difference was not statistically significant in our study. The most important determinants for hospitalisation duration are the presence of a tracheostomy and feeding tube dependence. In the robotic surgery group, we were able to discharge patients from the hospital sooner because of the lack of a tracheostomy and shorter swallowing recovery times. This finding is in accordance with the current literature. Park *et al.* reported that the average hospital stay for the transoral robotic surgery and open surgery groups was 18.6 days and 24.9 days, respectively.¹⁰

Two patients in the open supraglottic laryngectomy group and one patient in the transoral robotic supraglottic laryngectomy group suffered aspiration pneumonia. This difference was not significant. One might expect a higher number of cases of aspiration pneumonia in the transoral robotic surgery group because of the absence of a tracheostomy, but this was not the case. Our finding may be a result of shorter swallowing function recovery times in this group. Bleeding is another important issue in transoral robotic surgery. However, in our

relatively small number of cases, we did not encounter any bleeding following transoral robotic supraglottic laryngectomy.

The main limitation of our study is that it was not a prospective, randomised trial. In addition, the number of cases was relatively small. There is a need for larger series conducted in a prospective manner. Although our mean follow-up period is not short, it would be better to have five-year survival rates.

In this study, we evaluated the functional and oncological results of transoral robotic supraglottic laryngectomy and open supraglottic laryngectomy. In terms of the functional results, we showed that oral feeding time and mean hospitalisation duration were significantly shorter in the transoral robotic surgery group. No statistically significant differences were found for disease-specific survival and overall survival. These findings suggest that transoral robotic surgery offers similar oncological results to open surgery. Transoral robotic supraglottic laryngectomy is an oncologically and functionally safe procedure for T₁, T₂ and selected T₃ tumours of the supraglottic larynx.

Competing interests. None declared

References

- 1 Tomeh C, Holsinger FC. Laryngeal cancer. *Curr Opin Otolaryngol Head Neck Surg* 2014;**22**:147–53
- 2 Iqbal MS, Chaw C, Kovarik J, Aslam S, Jackson A, Kelly J *et al.* Primary concurrent chemoradiation in head and neck cancers with weekly cisplatin chemotherapy: analysis of compliance, toxicity and survival. *Int Arch Otorhinolaryngol* 2017;**21**:171–7
- 3 Rivelli TG, Mak MP, Martins RE, da Costa e Silva VT, de Castro Jr. G Cisplatin based chemoradiation late toxicities in head and neck squamous cell carcinoma patients. *Discov Med* 2015;**20**:57–66
- 4 Weinstein GS, O'Malley Jr BW, Snyder W, Hockstein NG. Transoral robotic surgery: supraglottic partial laryngectomy. *Ann Otol Rhinol Laryngol* 2007;**116**:19–23
- 5 Park YM, Kim WS, Byeon HK, Lee SY, Kim SH. Surgical techniques and treatment outcomes of transoral robotic supraglottic partial laryngectomy. *Laryngoscope* 2013;**123**:670–7
- 6 Ozer E, Alvarez B, Kakarala K, Durmus K, Teknos TN, Carrau RL. Clinical outcomes of transoral robotic supraglottic laryngectomy. *Head Neck* 2013;**35**:1158–61
- 7 Durmus K, Gokozan HN, Ozer E. Transoral robotic supraglottic laryngectomy: surgical considerations. *Head Neck* 2015;**37**:125–6
- 8 Park YM, Lee WJ, Lee JG, Lee WS, Choi EC, Chung SM *et al.* Transoral robotic surgery (TORS) in laryngeal and hypopharyngeal cancer. *J Laparoendosc Adv Surg Tech A* 2009;**19**:361–8
- 9 Alonso JM. Conservative surgery of cancer of the larynx. *Trans Am Acad Ophthalmol Otolaryngol* 1947;**51**:633–42
- 10 Park YM, Byeon HK, Chung HP, Choi EC, Kim SH. Comparison of treatment outcomes after transoral robotic surgery and supraglottic partial laryngectomy: our experience with seventeen and seventeen patients respectively. *Clin Otolaryngol* 2013;**38**:270–4
- 11 Mendelsohn AH, Remacle M. Transoral robotic surgery for laryngeal cancer. *Curr Opin Otolaryngol Head Neck Surg* 2015;**23**:148–52
- 12 Kayhan FT, Kaya KH, Altintas A, Sayin I. Transoral robotic supraglottic partial laryngectomy. *J Craniofac Surg* 2014;**25**:1422–6
- 13 Razafindranaly V, Lallemand B, Aubry K, Moriniere S, Vergez S, Mones ED *et al.* Clinical outcomes with transoral robotic surgery for supraglottic squamous cell carcinoma: experience of a French evaluation cooperative subgroup of GETTEC. *Head Neck* 2016;**38**:E1097–101
- 14 Mendelsohn AH, Remacle M, van der Vorst S, Bachy V, Lawson G. Outcomes following transoral robotic surgery: supraglottic laryngectomy. *Laryngoscope* 2013;**123**:208–14